

## Woman with abdominal distention

Mikaela Chilstrom · Jyoti Elavunkal ·  
Michael B. Stone

Received: 19 February 2010 / Accepted: 13 April 2010 / Published online: 8 June 2010  
© Springer-Verlag 2010

### Abstract

**Introduction** An 86-year-old woman presented to the Emergency Department after falling and being unable to get up. Her physical exam revealed massive abdominal distention and spider angiomata suspicious for possible ascites.

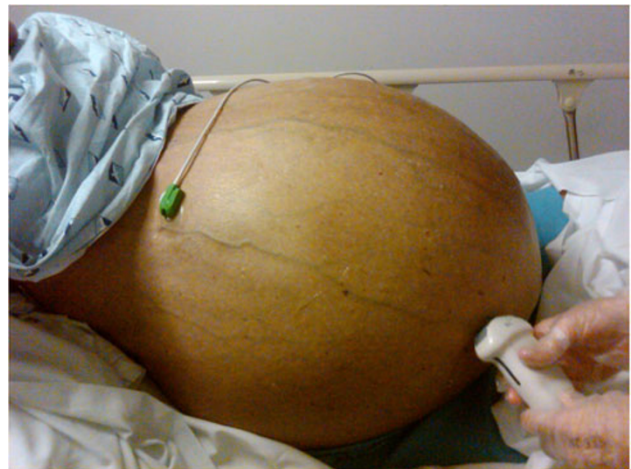**Materials and methods** The treating physician performed a bedside ultrasound that showed a discrete echogenic mass without evidence of ascites that was subsequently confirmed on computed tomography of the abdomen and pelvis.

**Conclusion** The utility of bedside ultrasound in the diagnostic evaluation of abdominal distention and possible ascites is discussed.

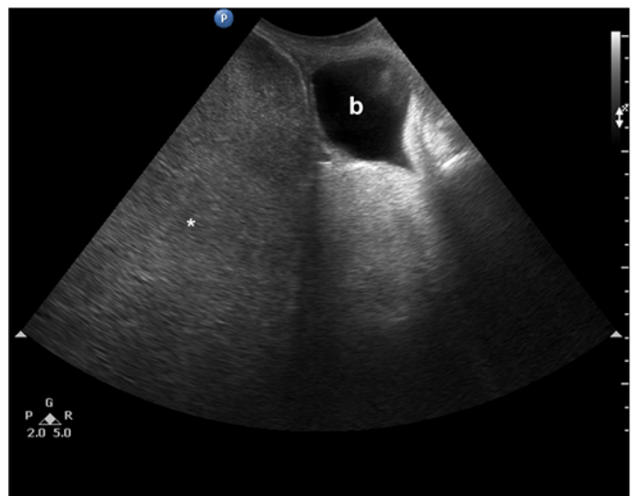
**Keywords** Emergency ultrasound · Critical ultrasound · Ascites · Ovarian tumor

### Case report

An 86-year-old woman presented via ambulance to the Emergency Department after falling and being unable to get up. She reported progressive abdominal distention and weight gain over the past several years, and stated that the weight of her abdomen had prevented her from standing up after her fall. She denied pain of any kind, but did report increasing dyspnea on exertion over the last few weeks. Physical findings included massive abdominal distention with spider angiomata (Fig. 1), decreased bowel sounds, and no tenderness to palpation. While considering a diagnostic and therapeutic paracentesis, the treating physician

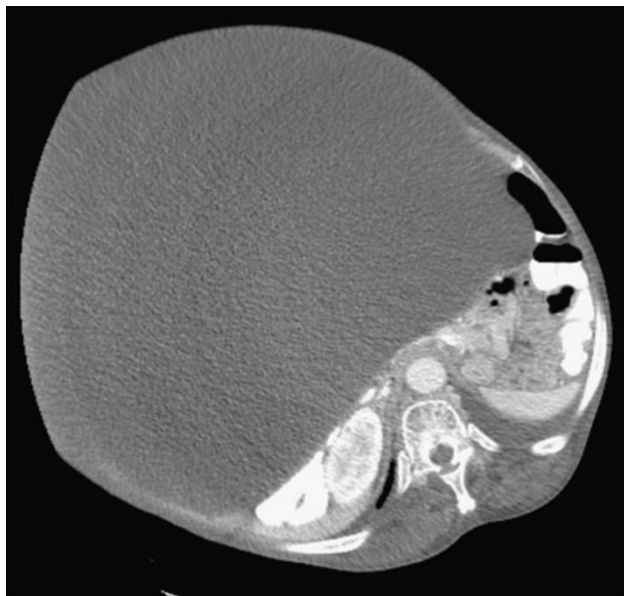


**Fig. 1** Patient's abdomen revealing massive distention and spider angiomata



**Fig. 2** Sagittal ultrasound of bladder (*b*) and the discrete echogenic mass (*asterisk*) superior to it

M. Chilstrom (✉) · J. Elavunkal · M. B. Stone  
Department of Emergency Medicine, SUNY Downstate/Kings  
County Hospital Center, Brooklyn, NY 11203, USA  
e-mail: mchilstrom@gmail.com



**Fig. 3** Computerized tomography scan of abdomen demonstrating mass

performed a bedside abdominal ultrasound that revealed a discrete echogenic mass without evidence of ascites (Fig. 2). Computed tomography of the abdomen and pelvis with oral and intravenous contrast demonstrated a large encapsulated cystic mass filled with complex fluid (Fig. 3). The patient was admitted to the hospital and subsequently had a total abdominal hysterectomy and bilateral salpingo-oophorectomy and 80-pound tumor debulking. The pathology of the pelvic mass revealed papillary serous carcinoma, poorly differentiated grade G3, FIGO Stage 1a.

## Conclusion

Several disease processes can mimic ascites including large pelvic masses, bowel obstruction, hepatic metastases, and massive hepatosplenomegaly. Attempted paracentesis in patients with these conditions could be catastrophic. While the physical exam can be helpful, it is neither sensitive nor specific for the presence of ascites [1, 2]. Prior research has suggested improved efficacy with the use of ultrasound prior to paracentesis [3, 4]. This case highlights the utility of bedside ultrasound in the diagnostic evaluation of abdominal distention and the importance of confirming ascites prior to paracentesis.

**Conflict of interest** None.

## References

1. Cummings S, Papadakis M, Melnick J, Gooding GA, Tierney LM Jr (1985) The predictive value of physical examinations for ascites. *West J Med* 142(5):633–636
2. Williams JW Jr, Simel DL (1992) The rational clinical examination. Does this patient have ascites? *JAMA* 267(19):2645–2648
3. Nazeer SR, Dewbre H, Miller AH (2005) Ultrasound-assisted paracentesis performed by emergency physicians vs the traditional technique: a prospective, randomized study. *Am J Emerg Med* 23(3):363–367
4. So CS, Schiedermayer D (2000) Pseudoascites in the clinical setting: avoiding unwanted and futile paracenteses. *WMJ* 99(6):32–34