

Emergency bedside ultrasound diagnosis of sub-massive acute pulmonary embolism: a case of the McConnell sign

Michael M. Liao · Jonathan Theoret ·
Elisa M. Dannemiller · Catherine Erickson ·
Geoffrey E. Sanz · John L. Kendall

Received: 11 February 2010 / Accepted: 13 April 2010 / Published online: 27 May 2010
© Springer-Verlag 2010

Abstract

Introduction This is a case of a healthy 61-year-old man with acute onset of dyspnea and atrial flutter where bedside emergency ultrasound was used to identify a classic echocardiographic finding called the “McConnell sign”. The clinical presentation and this echocardiographic finding led to the presumptive diagnosis of acute pulmonary embolism.

Materials and methods This is a case report and brief review of the literature.

Conclusion Bedside echocardiography has important diagnostic value in the evaluation of suspected acute pulmonary embolism. Findings, such as the McConnell sign are relatively quick and easy to identify at the bedside and could provide valuable information to rapidly guide management decisions when further research defines its role in emergent bedside ultrasound.

Keywords Emergency ultrasound · McConnell sign · Bedside · Pulmonary embolism · Diagnosis · Echocardiography

Case report

A 61-year-old athletic man presented to the emergency department (ED) by ambulance after becoming suddenly dyspneic. The patient was resting after completing a training session when he suddenly developed trouble breathing. His room air oxygen saturation was 98%, his heart rate 150, respiratory rate 55, blood pressure 155/68 and he was afebrile. The cardiac monitor showed new atrial flutter confirmed by electrocardiogram (ECG). Further history revealed that he had no risk factors for venous thromboembolic disease. A bedside echocardiogram (Supplementary Video 1; Fig. 1) was performed by the ED team and revealed a dilated right ventricle with right ventricular (RV) mid-free wall akinesis with normal RV apical contractility, a classic echocardiographic finding called “McConnell sign [1]”. Based on the clinical presentation and the bedside ultrasound findings, the decision was made to empirically anticoagulate for presumed acute pulmonary embolism. The patient was admitted to the medical intensive care unit. Secondary to renal insufficiency, a CT pulmonary angiogram (Fig. 2) was performed 2 days later showing large bilateral left main and right main pulmonary artery emboli, nearly occlusive and extending into almost all segmental arteries. A temporary inferior vena cava filter was placed in hospital, chronic warfarin was initiated, and his atrial flutter was rhythm and rate controlled with amiodarone and diltiazem, respectively. He was discharged home 9 days later without further events.

Electronic supplementary material The online version of this article (doi:10.1007/s13089-010-0028-1) contains supplementary material, which is available to authorized users.

M. M. Liao · J. Theoret · E. M. Dannemiller · C. Erickson ·
G. E. Sanz · J. L. Kendall (✉)
Department of Emergency Medicine, Denver Health Medical
Center, 777 Bannock Street, Mail Code 0108,
Denver, CO 80204, USA
e-mail: john.kendall@dhha.org

J. Theoret
Department of Emergency Medicine,
University of Alberta, Edmonton, AB, Canada

G. E. Sanz
Department of Emergency Medicine, Queen’s University,
Kingston, ON, Canada

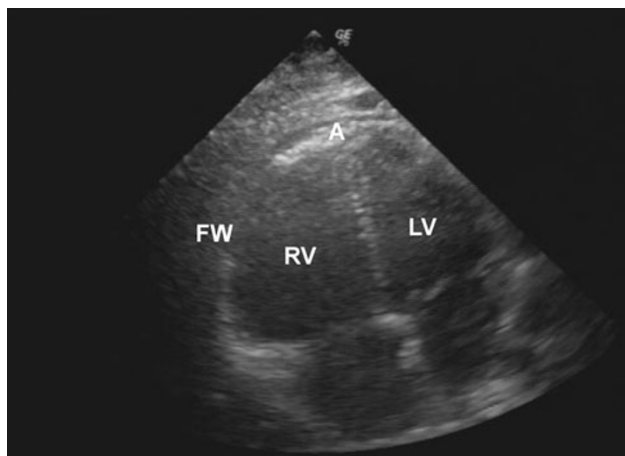


Fig. 1 Apical 4-chamber view of the heart. *RV* right ventricle (dilated), *LV* left ventricle, *A* apex (normal contraction), *FW* free wall of right ventricle (hypokinetic)

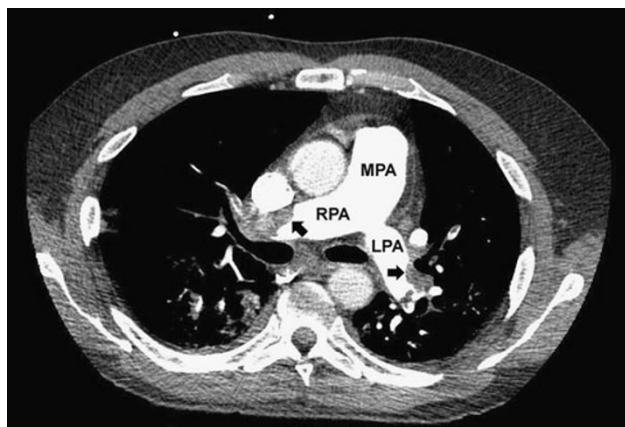


Fig. 2 Contrast-enhanced CT pulmonary angiogram. *MPA* main pulmonary artery, *RPA* right main pulmonary artery, *LPA* left main pulmonary artery, *arrows* pulmonary emboli

Discussion

Acute pulmonary embolism (APE) is a common and devastating disorder in the ED population, with a substantially increased risk of morbidity and mortality if missed or untreated in the ED [2]. Bedside echocardiography plays many important roles in the workup and management of APE, including diagnosis, prognosis, and guidance of aggressive therapy. Echocardiographic findings of APE are often indirect, unless a rare intracardiac thrombus is identified. The commonly identified findings include RV dysfunction, RV dilation, tricuspid regurgitation, and leftward septal displacement [3].

The diagnostic utility of echocardiography in an ED patient depends on whether the suspected APE is massive (i.e., associated with hypotension or shock) or sub-massive.

In the situation of suspected massive APE, echocardiography has a vital role. The European Society of Cardiology (ESC) Task Force for APE published guidelines in 2008 stating that “the absence of echocardiographic signs of RV overload or dysfunction practically excludes PE as a cause of hemodynamic compromise [4]”. Conversely, the presence of RV dysfunction on echocardiography could be used to presume massive APE and justify aggressive reperfusion therapy [4]. In addition, echocardiography could evaluate for other etiologies of hypotension, including cardiac tamponade, cardiogenic shock, or hypovolemia [5].

For the suspected sub-massive APE, as was the case in our patient, the diagnostic utility of echocardiography remains unclear. The ESC Task Force suggests that for patients with moderate or high pre-test probability of APE, a positive echocardiogram for RV dysfunction could be considered diagnostic [4]. However, a recent meta-analysis that pooled results from two prospective observational studies came to the conclusion that only patients with a high pre-test probability of APE could be accurately diagnosed with echocardiography [6]. Unfortunately evidence remains limited because of small sample sizes and heterogeneity of echocardiogram criteria for APE.

The McConnell sign was first described in 1996 as a distinct regional pattern of RV dysfunction (i.e., regional akinesis of the RV mid-free wall, but normal wall motion at the RV apex) that was more specific than simply RV dysfunction for APE [1]. Echocardiographic evidence of RV dysfunction is relatively common in APE, found in 40–70% of cases [7]. However, it is a relatively nonspecific finding, found also in cardiomyopathy, pulmonary hypertension, valvular heart disease, and RV infarction. McConnell and colleagues found this pattern to have a sensitivity of 77% (95% CI 46–94%) and a specificity of 94% (95% CI 86–98%). However, their study was small, consisting of 85 hospitalized patients with known RV dysfunction from any cause, of which 13 had acute pulmonary embolism [1].

Two subsequent studies have looked at the validity of McConnell sign for diagnosis of APE. In 2002, Kurzynia et al. prospectively evaluated 100 consecutive patients with suspected APE and found that the McConnell sign had a sensitivity of 19% (95% CI 11–31%) and a specificity of 100% (95% CI 87–100%) [8]. It should be noted that enrollment was at a tertiary hospital for referred pulmonary disease and only eight patients were enrolled directly from the ED. In 2005, Casazza et al. noted that the McConnell sign was found in 67% of patients retrospectively identified to have RV infarction, thus warning that McConnell sign lacks specificity in these patients [9]. However, this would suggest that patients with confirmed McConnell sign should also have an ECG with right sided leads to differentiate RV infarct from APE.

The McConnell sign to our knowledge has not been reported in the ED setting. Interestingly, Bova et al. suggest that using echocardiography alone to assess for RV dilation and/or Doppler evidence of pulmonary hypertension could reduce additional imaging workup by 12–28%, however will incorrectly treat 4–14% [10]. Perhaps, adding the McConnell sign to this suggested pathway could further reduce additional imaging or reduce false positives.

In summary, we present a case where bedside echocardiographic evidence of the McConnell sign led to a presumptive diagnosis of APE which was later confirmed on CT pulmonary angiogram. The diagnostic utility of echocardiography in patients suspected to have APE depends largely on the clinical presentation. In the hypotensive and unstable patient, it has tremendous diagnostic value. In the normotensive patient with suspected APE, its diagnostic value is less well established, but is likely dependent on the pre-test probability and useful mainly with a positive echocardiographic finding. Specific echocardiographic findings such as the McConnell sign are relatively quick and easy to identify at the bedside and thus could provide valuable information to rapidly guide management decisions if further research defines its role in emergent bedside ultrasound.

Acknowledgments Dr. Liao was supported by Agency for Healthcare Research and Quality (AHRQ) Grant F32-HS018123.

Conflict of interest None.

References

1. McConnell MV, Solomon SD, Rayan ME, Come PC, Goldhaber SZ, Lee RT (1996) Regional right ventricular dysfunction detected by echocardiography in acute pulmonary embolism. *Am J Cardiol* 78:469–473
2. Woo KM, Schneider JI (2009) High-risk chief complaints I: chest pain—the big three. *Emerg Med Clin North Am* 27:685–712
3. Miniati M, Monti S, Pratali L, Di Ricco G, Marini C, Formichi B, Prediletto R, Michelassi C, Di Lorenzo M, Tonelli L, Pistoletti M (2001) Value of transthoracic echocardiography in the diagnosis of pulmonary embolism: results of a prospective study in unselected patients. *Am J Med* 110:528–535
4. Torbicki A, Perrier A, Konstantinides S, Agnelli G, Galie N, Pruszczyk P, Bengel F, Brady AJ, Ferreira D, Janssens U, Klepetko W, Mayer E, Remy-Jardin M, Bassand JP, Vahanian A, Camm J, De Caterina R, Dean V, Dickstein K, Filippatos G, Funck-Brentano C, Hellemans I, Kristensen SD, McGregor K, Sechtem U, Silber S, Tendera M, Widimsky P, Zamorano JL, Andreotti F, Ascherman M, Athanassopoulos G, De Sutter J, Fitzmaurice D, Forster T, Heras M, Jondeau G, Kjeldsen S, Knuuti J, Lang I, Lenzen M, Lopez-Sendon J, Nihoyannopoulos P, Perez Isla L, Schwehr U, Torracca L, Vachieri JL (2008) Guidelines on the diagnosis and management of acute pulmonary embolism: the Task Force for the Diagnosis and Management of Acute Pulmonary Embolism of the European Society of Cardiology (ESC). *Eur Heart J* 29:2276–2315
5. Jones AE, Tayal VS, Sullivan DM, Kline JA (2004) Randomized, controlled trial of immediate versus delayed goal-directed ultrasound to identify the cause of nontraumatic hypotension in emergency department patients. *Crit Care Med* 32:1703–1708
6. Roy PM, Colombet I, Durieux P, Chatellier G, Sors H, Meyer G (2005) Systematic review and meta-analysis of strategies for the diagnosis of suspected pulmonary embolism. *BMJ* 331:259
7. ten Wolde M, Sohne M, Quak E, Mac Gillavry MR, Buller HR (2004) Prognostic value of echocardiographically assessed right ventricular dysfunction in patients with pulmonary embolism. *Arch Intern Med* 164:1685–1689
8. Kurzyna M, Torbicki A, Pruszczyk P, Burakowska B, Fijalkowska A, Kober J, Onisz K, Kuca P, Tomkowski W, Burakowski J, Wawrzynska L (2002) Disturbed right ventricular ejection pattern as a new Doppler echocardiographic sign of acute pulmonary embolism. *Am J Cardiol* 90:507–511
9. Casazza F, Bongarzone A, Capozzi A, Agostoni O (2005) Regional right ventricular dysfunction in acute pulmonary embolism and right ventricular infarction. *Eur J Echocardiogr* 6:11–14
10. Bova C, Greco F, Misuraca G, Serafini O, Crocco F, Greco A, Noto A (2003) Diagnostic utility of echocardiography in patients with suspected pulmonary embolism. *Am J Emerg Med* 21:180–183